34 The diagram shows a transverse section through a human bronchus.
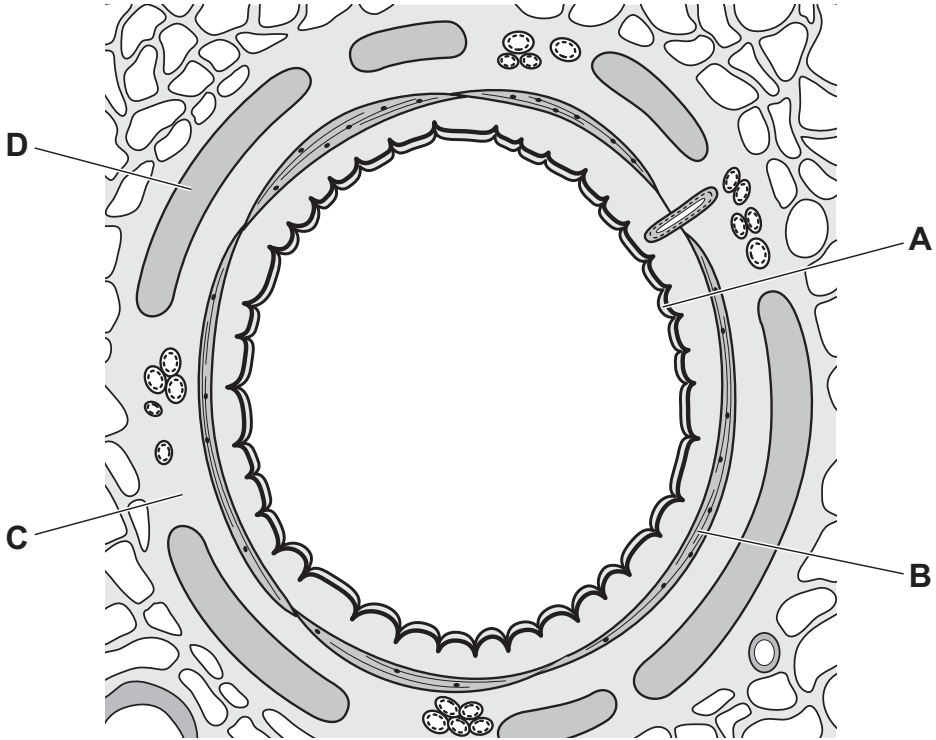
Which labelled tissue is the cartilage?