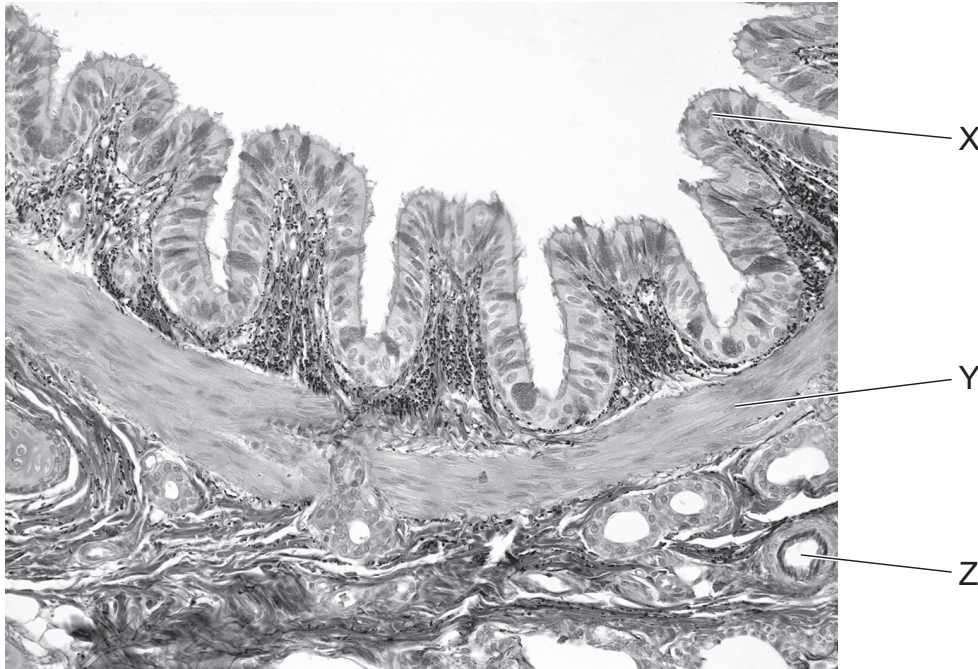


37 The photomicrograph shows the wall of a bronchus as seen with a light microscope.



Which row correctly identifies the structures labelled?

	X	Y	Z
A	epithelium	elastic fibres	bronchiole
B	endothelium	smooth muscle	bronchiole
C	epithelium	smooth muscle	blood vessel
D	endothelium	elastic fibres	blood vessel